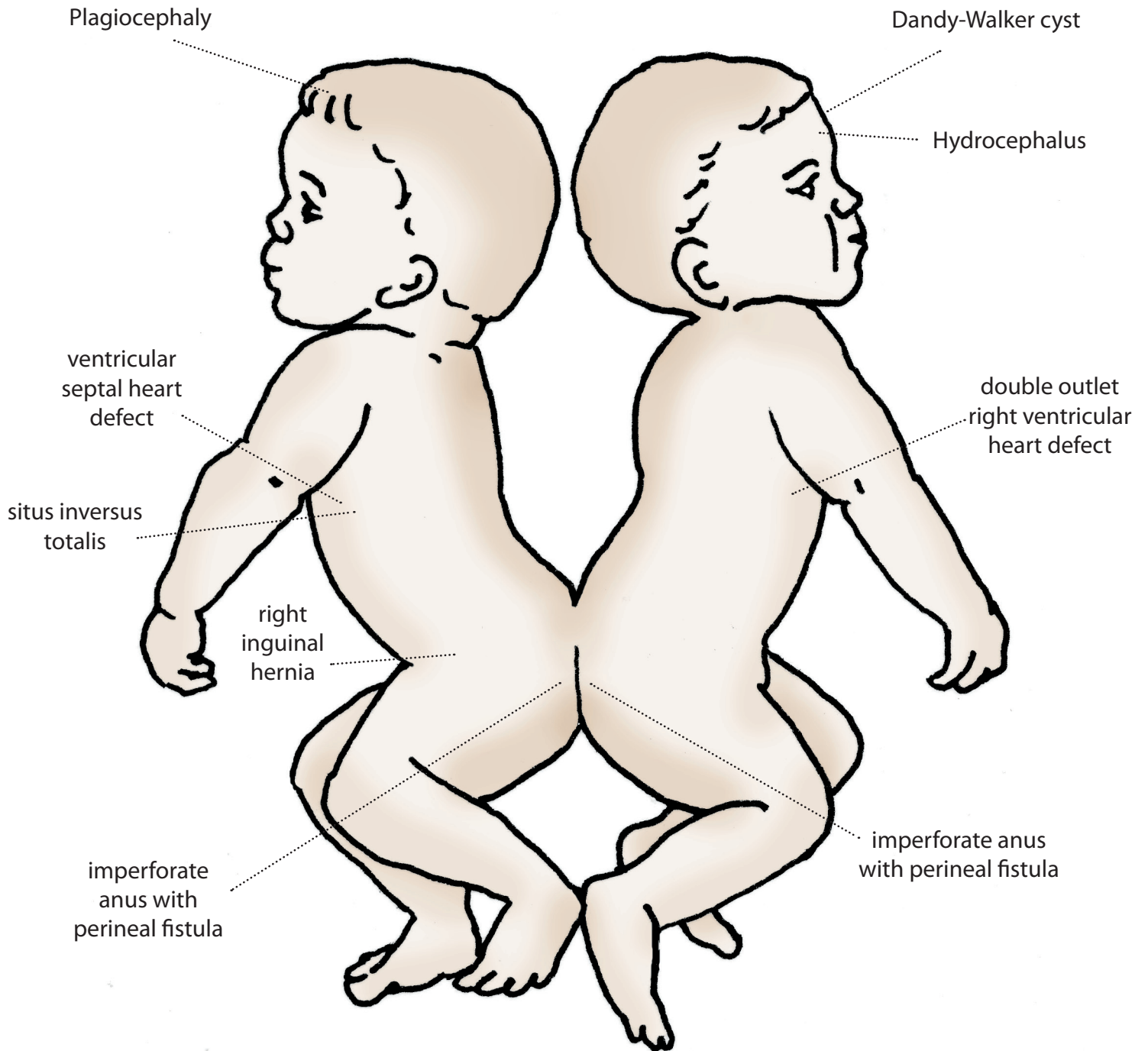


Pygopagus Conjoined Twins

Baby A
(Joshua)

Baby B
(Jacob)



Joined at the lumbar sacral spine
shared a rectum, muscle and nerves