Le Bonheur Children's Hospital
Memphis, Tennessee

PEDIATRIC ORTHOPAEDICS

Campbell Clinic® ORTHOPAEDICS

Summer 2016

Le Bonheur/Campbell Clinic team cares for increasing number of traumas

As the region's only American College of Surgeons (ACS)-designated Level 1 pediatric trauma center, Le Bonheur Children's Hospital treated more than 950 trauma-related orthopaedic injuries in 2015. It's been five years since Le Bonheur first attained ACS verification as a Level 1 pediatric trauma center. Since the designation, the hospital has seen a 60 percent increase in trauma patient volumes.

Case Study: Grace Bennett, 14

Grade 3B open femur fracture

Grace Bennett, 14, of Germantown, Tenn., was close to losing her left leg after an all-terrain vehicle (ATV) accident in November. Her mom, Shelbi Bennett, was at the grocery store with her younger daughter when she got the call.

"She had spent the night with a friend," said Shelbi. "They told me, 'Get here right now. Something's happened to Grace.'"

Her friend's mom and a doctor — who was nearby and happened to hear the accident — applied a tourniquet to stop the bleeding, while they waited for paramedics to arrive. Grace was airlifted to Le Bonheur Children's Hospital.

Grace suffered extensive soft tissue injury with a Grade 3B open femur fracture, said Le Bonheur/Campbell Clinic Pediatric Orthopaedic Surgeon Derek Kelly, MD. Her quadriceps mechanism and a large portion of her adductor compartment was disrupted. She also had extensive bone and muscle tissue loss. Her femoral artery and sciatic and femoral nerves were intact.

"She stood a very good chance of losing her leg," said Kelly.

Surgeons performed two surgeries to clean out and debride the dead tissue and bone to avoid infection. They also placed a temporary spanning external fixator during the first surgery to stabilize the injury.

Grace required two more surgeries, including a femoral rodding with masquelet technique for a 9 centimeter bone loss defect using antibiotic-impregnated bone cement. She also had a muscular and fascial repair of her quadriceps. Then, four weeks later, surgeons performed a bone grafting of the site following contralateral RIA bone graft harvest and removal of the bone cement spacer.

Initial injury film showing extensive soft tissue injury and bone loss

Most recent follow up radiograph showing complete cortical bridging laterally

Today, seven months after her accident, Grace is healing well. She still uses crutches to walk and does physical therapy twice a week to regain strength and function of her left leg.

"All in all she is doing great," said Kelly. "She has thus far avoided infection, and she has managed to heal part of her bone loss defect. Her rehab has been amazing, particularly considering that she had complete disruption of her quadriceps muscles with loss of tissue."

Grace, who started high school in August, continues to follow up in clinic every four to six weeks.

Case Study: Greg Smith, 16

C7 burst fracture, T1 compression fracture, cord compression

Greg Smith, 16, of Pontotoc, Miss., was returning home from a crawfish boil with a friend when their SUV hit a sudden sharp turn and rolled over. Greg managed to climb out of the vehicle from the passenger's seat.

"A lady who happened on the scene called me and told me he'd been an in accident, but that both boys were OK," said Greg's mom, Kristan Walker.



A CT scan at the nearest hospital revealed that Greg had a C7 burst fracture. He was transferred to Le Bonheur Children's Hospital, where further evaluation showed that Greg also had a small compression fracture of the T1 vertebra, as well as cord compression and gross instability.

"They told me it was a miracle he wasn't paralyzed," Kristan said.

Less than 48 hours after the accident, Orthopaedic Surgeon Jeffrey Sawyer, MD, and Neurosurgeon Michael Muhlbauer, MD, performed a C7 corpectomy to implant a Veristack spinal system, with the use of local autograft and allograft — as well an anterior cervical plating of C6-T1.

In a second surgery four days later, Orthopaedic Surgeon William Warner, MD, with Muhlbauer, performed a posterior spinal instrumentation fixation of C6-T1 in three segments with vertex lateral mass pedicle fixation.

After a 10-day hospital stay, Greg was able to return home, but remained in a neck brace for nearly three months as he healed. He's continued to follow up with both his pediatric neurosurgeon and pediatric orthopaedic surgeon at Le Bonheur to monitor his progress.

Greg, an active member of his school's band, was able to participate in band camp in July – one of his biggest goals for his recovery.

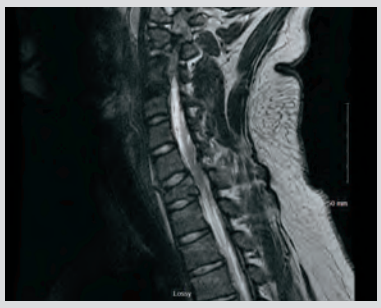

Preoperative MRI showing C7 fracture with spinal cord compression.
Postoperative radiographs following anterior and posterior spinal fusion and instrumentation.

BEST CHILDREN'S HOSPITALS U.S.News & WORLD REPORT ORTHOPEDICS 2016-17

lebonheur.org/ortho
campbellclinic.com

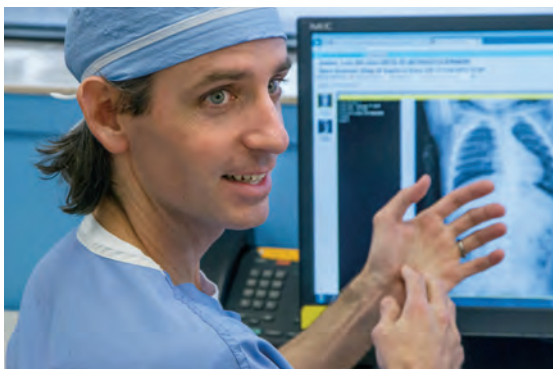

Derek Kelly, MD

Kelly travels Europe as POSNA fellow

Le Bonheur/Campbell Clinic Pediatric Orthpaedic Surgeon Derek Kelly, MD, was one of three surgeons selected for the Pediatric Orthopaedic Society of North America's (POSNA) traveling fellowship. Each year three POSNA members travel abroad, and three members of an international alliance society tour in North America.

Kelly visited four European medical centers and attended the annual European Pediatric Orthopaedic Society (EPOS) meeting in Rome.

Canale retires, receives prestigious Tipton Award



Terry Canale, MD

S. Terry Canale, MD, former professor and chair of the University of Tennessee-Campbell Clinic Department of Orthopaedic Surgery, recently retired after nearly 50 years of service to his patients and profession.

In March, Canale received the 2016 William W. Tipton Jr, MD, Leadership Award from the American Academy of Orthopaedic Surgeons (AAOS). Canale has served as former president for both the AAOS (2000-2001) and the Pediatric Orthopaedic Society of America (POSNA) (1989-1990). Canale was also the editor of *AAOS Now*.

"Terry is one of those individuals who, when recognized by his peers and put in a position of leadership, has not only actually done the job, but also has added vision and innovation and successful new ventures to every organization with which he has been involved," wrote current professor and chair of the Department of Orthopaedic Surgery James Beaty, MD, in his nominating letter.

Beaty named department chair for Orthopaedic Surgery, Biomedical Engineering

James H. Beaty, MD

James H. Beaty, MD, a Le Bonheur/Campbell Clinic pediatric orthopaedic surgeon, has been named chair of the University of Tennessee-Campbell Clinic Department of Orthopaedic Surgery and Biomedical Engineering in the College of Medicine at the University of Tennessee Health Science Center (UTHSC). He was also awarded the Harold B. Boyd, MD Professorship in Orthopaedic Surgery. Beaty, a UTHSC alum, is the ninth department chair since its founding in 1911.

Sawyer to serve as pre-course director at 2017 EPOSNA meeting

Jeffrey Sawyer, MD

Nearly 2,000 physicians are expected to attend the joint 2017 European Paediatric Orthopaedic Society (EPOS)/ Pediatric Orthpaedic Society of North America (POSNA) Annual Meeting in Barcelona May 3-6, 2017. Le Bonheur/Campbell Clinic Pediatric Orthopaedic Surgeon Jeffrey Sawyer, MD, was selected to chair the pre-course on "Cutting Edge Pediatric Orthopaedic Care: The North American and European Perspective." Sawyer also serves on the POSNA board of directors.

Rhodes receives Excellence in Advanced Practice award

Leslie Rhodes, NP

Leslie Rhodes, NP, recently received the 2016 Society of Pediatric Nursing's (SPN) national Excellence in Advanced Practice Award. The award recognizes an advanced practice nurse who has made a significant contributions to the care of children and their families. Rhodes is part of Le Bonheur's Pediatric Orthopaedic team and also serves as secretary of the Mid-South chapter of SPN. The award was presented at the SPN conference in April in Minneapolis.

Locke awarded for *Best Poster* at POPS conference

Lindsey Locke, NP

Orthopaedic Nurse Practitioner Lindsey Locke, NP, received a "Best Poster" award at the 2016 Pediatric Orthopaedic Practitioner Society (POPS) annual conference. For her study, "Evaluation of Nursing Education on the Utilization of a Pain Algorithm," Locke worked with a multidisciplinary team to help facilitate communication between providers and nurses to better control patients' pain.

Marielle Amoli, MD, sees patient Keegan Whitlow, 3, in clinic.

Fellowship Spotlight: Marielle Amoli, MD

Fellow Marielle Amoli, MD, fell in love with pediatric orthopaedics during her final year of medical school. A month-long rotation with the Le Bonheur/Campbell Clinic team left Amoli ready to pursue the specialty as a career.

"Instantly, I loved the variety of procedures and children you see. I wanted the ability to help them," said Amoli.

After completing medical school at the Medical College of Georgia, Amoli was accepted into the University of Florida-Jacksonville's orthopaedic surgery residency program. After completing the program, she knew she wanted to return to Le Bonheur/Campbell Clinic for further training in pediatrics.

"I knew I wanted to come back here ever since my first experience with Le Bonheur/Campbell Clinic as a medical student," said Amoli. "All of the attendings are wonderful and fully committed to patient care and resident/fellow teaching."

Upon completing her fellowship, Amoli plans to return to Jacksonville, Fla., to work as a pediatric orthopaedic surgeon at Nemours Children's Clinic.

"I'm excited to get back home, but will miss everyone I've met and had the opportunity to work with here. I plan on incorporating everything I've learned here both in the OR and the clinic into my practice back in Florida," said Amoli.

Research Spotlight: 2016

The Le Bonheur/Campbell Clinic Pediatric Orthopaedic team delivered several podium and poster presentations at the 2016 Pediatric Orthopaedic Society of North America (POSNA) annual meeting in April. Podium presentations included:

"Factors that predict instability in pediatric diaphyseal both-bone forearm fractures"

Age, initial translation, complete fractures of the radius and residual translation on follow-up are all factors that predict need for a repeat procedure in pediatric patients with diaphyseal forearm fractures. Researchers looked at radiographs and records of 188 patients (174 with adequate follow-up) with closed reduction and casting of diaphyseal forearm fractures in the emergency department to determine what factors may predict failure of initial closed reduction and casting. Demographic, time course and radiographic data were evaluated at presentation and at varying intervals until union was achieved. Risk factors for repeat reduction include:

- Fractures translated 50 percent or more in any plane
- Age greater than 9 years
- Complete fracture of the radius
- Follow-up angulation of the radius of more than 15 degrees on lateral radiographs
- Follow-up angulation of the ulna of more than 10 degrees on anteroposterior radiographs
- Translation of either bone of more than 50 percent at follow-up

"Pediatric femur fracture management: A multicenter analysis of the trends pre and post 2009 AAOS Clinical Practice Guidelines"

Results of a multicenter study analyzing treatment of nearly 2,700 pediatric femoral shaft fractures in a 10-year period show a continued trend toward operative management of femoral shaft fractures in younger children. The study looked at treatment of such fractures five years before and five years after (2004-2013) the American Academy of Orthopaedic Surgeons (AAOS) released its Clinic Practical Guidelines (CPG) in 2009.

After 2009, data showed significant increases in locked intramedullary nailing in patients younger than 11 years old and a trend toward surgical treatment in patients younger than 5 years old. The study revealed considerable variability in treatment method and adherence to the CPG among centers.

"Child safety restraint status and age in motor vehicle collisions predict type and severity of traumatic injuries"

Researchers retrospectively reviewed charts for patients ages 12 and younger (967 patients) who were treated after a motor vehicle collision (MVC) to evaluate the relationship between childhood MVC injuries, age and restraint status. Age groupings were established in accordance with the state's child safety restraint laws. Restraint status groupings were also assigned to each patient based upon the trauma registry data. Data analysis was performed with cross tables and a Chi Squared test. The study found that:

- 4-8-year-olds were most commonly improperly restrained
- No statistical difference was observed for orthopaedic injuries among restraint status groups
- Internal thoracic injuries, open head wounds and open upper-extremity wounds were most common injuries in improperly and unrestrained patients
- Upper-extremity fractures, femur fractures, dislocations and spinal fractures were significantly higher in older age groupings
- Improperly restrained infants had higher occurences of intracranial bleeds and abrasions

"Issues affecting the practice of pediatric orthopaedic surgeons: Results of the 2014 workforce survey of the American Academy of Pediatrics Section on Orthopaedics"

Work volume and complexity continue to increase, despite increased perception of local competiton among orthopaedic surgeons, according to an analysis of the 2014 workforce survey of the American Academy of Pediatrics Section on Orthopaedics. The analysis also found that there are more female pediatric orthopaedic surgeons (23 percent in 2014 compared to 8 percent in 1998) and an insignificant change in work hours per week and main practice locations compared to previous reports.

Comparing 2014 to 1998 | *Results of the AAP's orthopaedic workforce survey*

	FOPE II study	2014 AAP/POSNA survey	Change
Female participants	8%	23%	15%
Hours worked	62 hours	60 hours	-2 hours
Work in University/ academic setting	42%	43%	1%
Work in multispecialty group	35%	33%	-2%
Perceive increase in volume or complexity	55%	30%	-25%
Perception of local competition	81%	74%	-7%
Local competition with pediatric orthopedic surgeons	71%	90%	18%

"Complications and radiographic outcomes of posterior spinal fusion (PSF) and observation (OBS) in patients who have undergone distraction-based treatment for early onset scoliosis (EOS)"

Observation, in select patients, at the end of distraction gives similar radiographic and spine height outcomes as patients who undergo posterior spinal fusion (PSF), which has a much greater complication rate.

Researchers reviewed data from the Children's Spine Study Group database for 37 patients who underwent observation (12 patients) or PSF (25 patients) at the end of distraction to compare radiographic and spine length parameters and complications. Findings include:

- The most common CEOS diagnosis was C3.
- Mean age of initiation of distraction was 4.2 years in both groups.
- The groups were similar in terms of ambulation and device (rib-based 100 percent PSF, 84 percent OBS).
- While PSF led to initial improvement in radiographic and length/height, at final follow-up, there was no significant difference between the groups in terms of cobb angle/kyphosis and T1-T12 height/length.
- The groups were similar radiographically, and OBS patients achieved 90 percent T1-L1 length as PSF.
- There were 62 and 0 complications in the PSF/OBS groups.

Further study is necessary to determine factors predictive successful long term observation.

Ortho recognized by *U.S. News & World Report*

U.S. News & World Report has again named the Le Bonheur/Campbell Clinic pediatric orthopaedic team as one of the nation's best programs. The 2016-17 Best Children's Hospital rankings were released June 21.

"The *U.S. News* designation is further proof that Le Bonheur provides world-class pediatric health care to children in Memphis, the region and the country. This badge means that parents can trust that our experts work every day to be one of the best children's hospitals in the country," said Le Bonheur President and CEO Meri Armour. "We use the *U.S. News* survey standard as a tool to continually advance the level of our pediatric care. We are honored that Le Bonheur has been recognized seven of the nine categories in which we could apply."

Le Bonheur
Children's Hospital

Campbell Clinic
ORTHOPAEDICS

848 Adams Avenue
Memphis Tennessee 38103

@lebonheurchild /lebonheurchildrens /lebonheurchildrens /lebonheurchildrens

Research, Publications and Presentations

Le Bonheur Children's Hospital and Campbell Clinic's five surgeons are actively involved in research and presentations in the pediatric orthopaedic field. Highlights from their work are listed below:

Publications

Fracture of the Medial Humeral Epicondyle in Children: A Comparison of Operative and Non-operative Management. Biggers M, Bert T, Moisan A, Spence DD, Warner WC Jr, Beaty JH, Sawyer JR, Kelly DM. Journal of Southern Orthopaedic Advances. Fall 2015 Vol 24. No. 3. 188.

The Limping Child: A Systematic Approach to Diagnosis. Naranje S; Kelly DM, Sawyer JR. Am Fam Physician. 2015 Nov 15;92(10):908-16.

The Classification for Early Onset Scoliosis Predicts Timing to VEPTR Anchor Failure. Park HY, Matsumoto H, Feinberg N, Roye DP, Kanj WW, Betz RR, Cahill PJ, Glotzbecker MP, Luhmann SJ, Garg S, Sawyer JR, Smith JT, Flynn JM, Vitale MG. J Pediatr Orthop. 2015 Nov 13. [Epub ahead of print]

Complications After Surgical Treatment of AIS. de MendonÃ§a RG, Sawyer JR, Kelly DM. Orthop Clin North Am. 2016 Apr;47(2):395-403.

Retrospective: Impact of child safety restraint status during motor vehicle collisions (MVC) in predicting type and severity of bone fractures and other trauma UTHSC IRB# 14-03310-XM. Chris Loftis, JRS, Trey Eubanks, DMK. J Pediatr Orthop. 2016 Jan 11. [Epub ahead of print].

Comparison of Two Post-Operative Bowel Regimens in Children with Scoliosis Repair. Rhodes LN, Loman DG, Bultas MW. Orthop Nurs. 2016 Jan-Feb;35(1):13-7.

Complications Related to the Treatment of Slipped Capital Femoral Epiphysis. Roaten J, Spence DD. Orthop Clin North Am. 2016 Apr;47(2):405-13. doi: 10.1016/j.ocl.2015.09.013. Review.

Cervical Spine Trauma Immobilization Protocols in Young Children: How Often are These Protocols Followed? IRB#14-03323-XM 8/13/2014. WCW, Eric Weldy. COJ Volume 2, 2016.

Adolescent Idiopathic Scoliosis Treated with Simultaneous Translation on Two Rods (ST2R) with Preoperative, Postoperative and Follow-up Evaluation by EOS 3D Imaging: A Pilot Study. De MendonÃ§a RG, Hong VY, Flournoy JM, Sawyer JR, Kelly DM. COJ Volume 2, 2016.

Levels of Evidence in the Journal of Pediatric Orthopaedics: Update and Comparison to the Journal of Bone and Joint Surgery. Murphy RF, Cibulas AM, Sawyer JR, Spence DD, Kelly DM. J Pediatr Orthop. 2015 Oct/Nov 35(7):779-781

Business and Practice Management Knowledge Deficiencies in Graduating Orthopedic Residents. Miller DJ, Throckmorton TW, Azar FM, Beaty JH, Canale ST, Richardson DR. Am J Orthop (Belle Mead NJ). 2015 Oct;44(10):E373-8.

Reliability analysis of Cobb angle measurements of congenital scoliosis using X-ray and 3D-CT images. Tauchi R, Kawakami N, Tsuji T, Cahill PJ,Flynn JM, Flynn, Glotzbecker M, El-Hawary R, Heflin JA, Imagama S, Joshi AP, Nohara A, Ramirez N, Roye DP, Saito T, Sawyer JR, Smith JT. Eur J Orthop Surg Traumatol. 2015 Sep 16. [Epub ahead of print]

Changes in the Treatment of Pediatric Femur Fractures: Trends from United States Kids' Inpatient Database (KID). Naranje SM, Stewart MG, Kelly DM, Jones TL, Spence DD, Warner WC Jr, Beaty JH, Sawyer JR. J Pediatr Orthop. 2015 Aug 28. [Epub ahead of print]

Epidemiology of pediatric fractures presenting to Emergency Department for United States population. Sameer M Naranje, Richard A Erali, DDS, WCW, JHB, JRS, DMS. J Pediatr Orthop. 2015 Jul 14. [Epub ahead of print].

Uniplanar Versus Taylor Spatial Frame External Fixation For Pediatric Diaphyseal Tibia Fractures: A Comparison of Cost and Complications. Shore BJ, DiMauro JP, Spence DD, Miller PE, Glotzbecker MP, Spencer S, Hedequist D. J Pediatr Orthop. 2015 Jun 17. [Epub ahead of print]

Atypical Neurologic Deficits Following Posterior Spinal Fusion Including Ponte Osteotomies for Idiopathic Scoliosis-A Report of Two Cases (UTHSC IRB#12-02297-XM). Barkoh K, Kelly DM, Warner WC Jr., Meier J, Sawyer JR , Chan G. Campbell Orthopaedic Journal 2015.

Use of Vertical Expandable Prosthetic Titanium Rib (VEPTR) in the Treatment of Congenital Scoliosis Without Fused Ribs. Murphy RF, Moisan A, Kelly DM, Warner WC Jr, Jones TL, Sawyer JR. J Pediatr Orthop. 2015 Apr 13. [Epub ahead of print]

Early Career Experience of Pediatric Orthopaedic Fellows: What to Expect and Need for Their Services. Glotzbecker M, Shore B, Fletcher N, Larson N, Hydorn C, Sawyer JR. Published JPO 2015 Mar 3. [Epub ahead of print]

Interobserver and intraobserver reliability of the modified waldenström classification system for staging of legg-calvé-perthes disease. Hyman JE, Trupia EP, Wright ML, Matsumoto H, Jo CH, Mulpuri K, Joseph B, Kim HK; International Perthes Study Group Members. J Bone Joint Surg Am. 2015 Apr 15;97(8):643-50. doi: 10.2106/JBJS.N.00887.

Outcomes and Complications of Tibial Tubercle Fractures in Pediatric Patients: A Systematic Review of the Literature. Pretell-Mazzini J, Kelly DM, Sawyer JR, Esteban EM, Spence DD, Warner WC Jr, Beaty JH. J Pediatr Orthop. 2015 Apr 10. [Epub ahead of print]

Osteonecrosis After Femoral Neck Fractures in Children and Adolescents: Analysis of Risk Factors. Spence DD; DiMauro JP; Miller P, Glotzbecker MP; Hedequist D, Shore BJ.

Transverse Femoral Shaft Fractures are a Better Predictor of Non-Accidental Trauma than Spiral Fractures in Young Children. Kelly DM, Murphy R, Warner WC Jr., Moisan A, Thompson N, Spence DD, Beaty JH, Sawyer JR. J Bone Joint Surg Am. 2015 Jan 21;97(2):106-11.

Gunshot-associated fractures in children and adolescents treated at two Level 1 pediatric trauma centers UTHSC IRB 11-01515-XM (1/18/12). Naranje SM, Stewart MG, Rush JK, Bleakney C , Mckay , Gilbert SR, Spence DD, Warner WC, Sawyer JR. J Pediatr Orthop. 2015 Jan 28. [Epub ahead of print].

A multidisciplinary approach to providing care to adolescents with spinal cord trauma resulting from all-terrain vehicle (ATV) accidents: A case study. Rhodes LN, Weatherford B, Locke LN, Chung HS, Tidwell C, Paton E, Lee S. J Trauma Nurs. 2015 Jan-Feb;22(1):23-7.

Sub-axial cervical spine injuries in children and adolescents UTHSC IRB: 13-02544-XM. Murphy RF, Davidson AR, Warner WC Jr, MD, Kelly DM, Spence DD, Sawyer JR. J Pediatr Orthop. 2015 Mar;35(2):136-9.

Altered lower extremity fracture characteristics in obese pediatric trauma patients. Gilbert SR, Maclennan PA, Backstrom I, Creek A, Sawyer J. J Orthop Trauma. 2015 Jan;29(1):e12-7.

Supracondylar Fractures with Isolated Anterior Interosseous Nerve Injuries: Are they Urgent Cases? UTHSC IRB#13-02587-XM 7/23/2013. Barrett KK, Skaggs DL, Sawyer JR, Andras L, Moisan A, Goodbody C, Flynn J. J Bone Joint Surg Am, 2014 Nov 05;96(21):1793-1797.

Unicameral Bone Cysts: General Characteristics and Management Controversies. Juan Pretell, Robert F Murphy,Indranil Kushare, DNB, DOrtho, John P. Dormans, MD. JAAOS May 1, 2014; 22 (5).

Surgical Treatment of Symptomatic Accessory Navicular in Children and Adolescents. (UTHSC IRB# 12-02032-XM 9-4-2012). Pretell, Murphy, Sawyer, Spence, Warner, Beaty, Moisan, Kelly. A J Ortho. 2014 Mar;43(3):110-3.

Intraobserver and Interobserver Reliability and the Role of Fracture Morphology in Classifying Femoral Shaft Fractures in Young Children. Thompson NB, Kelly DM, Warner WC Jr, Rush JK, Moisan A, Hanna WR Jr, Beaty JH, Spence DD, Sawyer JR. J Pediatr Orthop. 2014 Apr-May;34(3):352-8.

Characterization of Radiation Exposure in Early-Onset Scoliosis Patients Treated With the Vertical Expandable Prosthetic Titanium Rib (VEPTR). Cannon TA, Neto NA, Kelly DM, Warner WC Jr, Sawyer JR. J Pediatr Orthop. 2014 Mar;34(2):179-84.

The Efficacy of Rib-Based Distraction with VEPTR in Treatment of Early_Onset Scoliosis in Patients with Arthrogryposis. MHIRB 2006-022 (5/25/06). Flynn, John M; Flynn, John M.; Glotzbecker, Michael; van Bosse, Harold J.; Hoashi, Jane S.; d'Amato, Charles R.;Moisan, Alice; Kelly, Derek M.; Warner, William C.; Sawyer, Jeffrey R. J Pediatr Orthop. 2014 Jan;34(1):8-13.

Murphy RF1, Cibulas AM, Sawyer JR, Spence DD, Kelly DM. Levels of Evidence in the Journal of Pediatric Orthopaedics: Update and Comparison to the Journal of Bone and Joint Surgery. J Pediatr Orthop. 2014 Nov 19. [Epub ahead of print]

Murphy RF, Davidson AR, Kelly DM, Warner WC Jr, Sawyer JR. Subaxial Cervical Spine Injuries in Children and Adolescents. J Pediatr Orthop. 2014 Nov 6. [Epub ahead of print]

Barrett KK, Skaggs DL, Sawyer JR, Andras L, Moisan A, Goodbody C, Flynn JM. Supracondylar Humeral Fractures with Isolated Anterior Interosseous Nerve Injuries: Is Urgent Treatment Necessary? J Bone Joint Surg Am, 2014 Nov 05;96(21):1793-1797.

Murphy W, Naranje SM, Kelly DM, Spence DS, Warner WC Jr, Beaty JH, Sawyer JR. Nonaccidental traumatic dislocation of the hip in a 3-year-old child: a report of a rare pediatric injury. Am J Orthop (Belle Mead NJ). 2014 Aug;43(8):374-6.

Rhodes L, Nash C, Moisan A, Scott DC, Barkoh K, Warner WC Jr, Sawyer JR, Kelly DM. Does Preoperative Orientation and Education Alleviate Anxiety in Posterior Spinal Fusion Patients? A Prospective, Randomized Study. J Pediatr Orthop. 2014 Jul 17. [Epub ahead of print]

Systemic Clostridium Toxicity Resulting from a Knee Laceration in a Pediatric Patient. Fesmire A, Sawyer JR, Warner WC, Buckingham S, Bagga B, Anand K, Kelly DM. Journal of Pediatric Infectious Diseases 9 (2014) 31-35

The Use of Magnetic Resonance Imaging in the Evaluation of Spondylolysis. Rush JK, Astur N, Scott S, Kelly DM, Sawyer JR, Warner WC. Jr. J Pediatr Orthop. 2014 June 24. [Epub ahead of print]

Accessibility and Quality of Online Information for Pediatric Orthopaedic Surgery Fellowships. Davidson AR, Murphy RF, Spence DD, Kelly DM, Warner WC Jr, Sawyer JR. J Pediatr Orthop. 2014 May 19. [Epub ahead of print]

Traumatic Atlanto-occipital Dislocation in Children. Astur N, Sawyer JR, Klimo P, Kelly DM, Muhlbauer M, Warner WC. *J Am Acad Orthop Surg* May 2014 ; 22:274-282.; doi:10.5435/JAAOS-22-05-274

Altered lower extremity fracture characteristics in obese pediatric trauma patients. Gilbert SR, Maclennan PA, Backstrom I, Creek A, Sawyer J. J Orthop Trauma. 2014 Apr 15. [Epub ahead of print]

Current State of Pediatric Orthopaedic Disaster Response. Kelly DM, Heyworth BE, Kruse RW, Edmonds EW, VanderHave K, Podeszwa DA, Talwalkar VR, Warner WC Jr, Gordon JE. J Pediatric Orthop.2014 Apr-May;34(3):231-8

Intra-observer and Inter-observer Reliability and the Role of Fracture Morphology in Classifying Femoral Shaft Fractures in Young Children. Thompson NB, Kelly DM, Warner WC Jr, Rush JK, Moisan A, Hanna WR, Beaty JH, Spence DD, Sawyer JR. J Pediatr Orthop. 2013 Oct 29. [Epub ahead of print]

Current State of Pediatric Orthopaedic Disaster Response. Pediatric Orthopaedic Society of North America Trauma and Prevention Committee 2011-2012. Kelly DM, Heyworth BE, Kruse RW, Edmonds EW, VanderHave K, Podeszwa DA, Talwalkar VR, Warner WC Jr, Gordon JE; J Pediatric Orthop. 2013 Oct 29. [Epub ahead of print]

Characterization of Radiation Exposure in Early Onset Scoliosis Patients Treated With the Vertical Expandable Prosthetic Titanium Rib (VEPTR). Cannon TA, Astur N, Kelly DM, Warner WC Jr, Sawyer JR. J Pediatr Orthop. 2013 Oct 29. [Epub ahead of print]

Weight Gain During External Fixation. Culotta, B; Gilbert, SR; Sawyer, JR: Ruch, A; Sellers, T. Journal of Children's Orthopedics, March 2013, Volume 7, Issue 2, pp 147-150.

Pulseless Extremity Following an Apparently Non-displaced Proximal Humeral Physeal Fracture: A Case Report. Hall JM, Sawyer JR, Warner WC Jr., Moisan A, Kelly DM. JBJS Case Connector, 2013 Sep 11;3(3):e90 1-4

Medial Ulnar Collateral Ligament Origin in Children and Adolescents: An MRI Anatomic Study. Larsen N, Moisan A, Witte D, Ellzey A, Sawyer JR, Warner WC Jr, Beaty JH, Kelly DM. J Pediatr Orthop. 2013 Sep;33(6):664-6.

Treatment of Pediatric Femur Fractures with the Pavlik Harness: Multiyear Clinical and Radiographic Outcomes. Rush JK, Kelly DM, Sawyer JR, Beaty JH, Warner WC Jr. J Pediatr Orthop. 2013 Sep; 33(6):614-7

Atypical presentation of an osteoid osteoma in a child revisited. Sawyer JR. Am J Orthop (Belle Mead NJ). J Pediatr Orthop. 2013 Jan;42(1):19.

Associated injuries in children and adolescents with spinal trauma. Rush JK, Kelly DM, Astur N, Creek A, Dawkins R, Younas S, Warner WC Jr, Sawyer JR. J Pediatr Orthop. 2013 Jun;33(4):393-7. doi: 10.1097/BPO.0b013e318279c7cb.

An accessory limb with lipomyelomeningocele in a male. Murphy RF, Cohen BH, Muhlbauer MS, Eubanks JW 3rd, Sawyer JR, Moisan A, Kelly DM. Pediatr Surg Int. 2013 Jul;29(7):749-52. doi: 10.1007/s00383-013-3269-9. Epub 2013 Feb 8.

Presentations

Jim Beaty, MD

Beaty, JH, Jeffrey I Kutsikovich, MD, Christopher M Hopkins, MD, Edwin W Gannon III, William C Warner, MD, Jeffrey R Sawyer, MD, David D Spence, MD, Derek M Kelly, MD. Factors that Predict Instability in Pediatric Diaphyseal Both Bone Forearm Fractures. ASSH ePoster. Sep 10-12. Seattle, WA.

Cervical Spine Trauma Immobilization Protocols in Young Children. How Often Are These Protocols Followed? Factors that Predict Instability in Pediatric Diaphyseal Both Bone Forearm Fractures. Weldy, Beaty, Spence, Kelly, Sawyer, Warner, Jr. OTA poster. San Diego, CA. Oct. 7-10, 2015.

Factors that Predict Instability in Pediatric Diaphyseal Both Bone Forearm Fractures. Kutsikovich, Hopkins, Gannon III, Beaty, Warner, Sawyer, Spence, Kelly. ASSH eposter. Seattle, WA. Sept. 10-12, 2015; OTA podium. San Diego, CA. Oct. 7-10, 2015.

Beaty J, Bert, Biggers, Moisan, Sawyer, Warner, Kelly. Fracture of the Medial Humeral Epicondyle in Children: A Comparison of Operative and Nonoperative Management (accepted Podium). American Academy of Orthopaedic Surgeons, New Orleans, March 2014.

Beaty, Thompson, Kelly, Rush, Warner, Spence, Moisan, Sawyer. Intra and Inter-Observer Reliability and the Role of Fracture Morphology in Classifying Femoral Shaft Fractures in Children (poster). European Pediatric Orthopaedic Society, Belgium, April 2014.

Beaty James H. MD, Ryan Murphy BS, Derek M. Kelly MD, William C. Warner Jr. MD, Alice Moisan RN, Norfleet Thompson MD, David D. Spence MD, Jeffrey R. Sawyer MD. Transverse Femoral Shaft Fractures are a Better Predictor of Non-Accidental Trauma than Spiral Fractures in Young Children(poster). European Pediatric Orthopaedic Society, Belgium, April 2014.

Beaty James H. MD, Byron F. Stephens MD, Jeffrey R. Sawyer MD, William C. Warner MD, David D. Spence MD, Alice A. Moisan BSN and Derek M. Kelly MD Interleukin-6 in Pediatric Musculoskeletal Infection: A Pilot Study (Podium). European Pediatric Orthopaedic Society, Belgium, April 2014.

Beaty James H. MD, Sameer M. Naranje MD, Derek M. Kelly MD, Jeffrey R. Sawyer MD, Tamekia L. Jones PhD. Changes in the Treatment of Pediatric Femur Fractures: Trends from United States Kids' Inpatient Database (KID) (Podium). European Pediatric Orthopaedic Society, Belgium, April 2014.

Beaty James H, MD, Juan Pretell-Mazzini, MD, Vinayak Perake, MD; Derek M. Kelly, MD, Jeffrey R Sawyer, MD, Alice A Moisan, BSN, David D Spence, MD, William C Warner, Jr, MD. Outcomes And Complications Of Tibial Tubercle Fractures Within The Pediatric Population. A Systematic Review Of The Literature (e-poster). European Pediatric Orthopaedic Society, Belgium, April 2014.

Beaty James H. MD, Ryan Murphy BS, Derek M. Kelly MD, William C. Warner Jr. MD, Alice Moisan RN, Norfleet Thompson MD, David D. Spence MD, Jeffrey R. Sawyer MD Transverse Femoral Shaft Fractures are a Better Predictor of Non-Accidental Trauma than Spiral Fractures in Young Children accepted podium. POSNA, Hollywood, Ca., April-May 2014.

Beaty James H. MD, Byron F. Stephens MD, Jeffrey R. Sawyer MD, William C. Warner MD, David D. Spence MD, Alice A. Moisan BSN and Derek M. Kelly MD. Interleukin-6 in Pediatric Musculoskeletal Infection: A Pilot Study accepted e poster. POSNA, Hollywood, Ca., April-May 2014.

Beaty, J. Advocacy for Orthopaedic Surgeons. IPOS. December 4-7, 2013. Lake Buena Vista, Fla.

Beaty, J. Case Presentations. IPOS. December 4-7, Lake Buena Vista, Fla.

Beaty, J. Slipped capital femoral epiphysis: Update. Pediatric Orthopaedics: Common Conditions and the Pediatric Hip, Le Bonheur, November 2, 2013.

Beaty, J. Frequently missed upper extremity fractures. Pediatric Orthopaedics: Common Conditions and the Pediatric Hip, Le Bonheur, November 2, 2013.

Beaty, J. Sports Injuries in Children and Adolescents: 2013 Update. Etteldorf Symposium 2013, Le Bonheur, May 2013.

Beaty, J. The Othopaedic Lecture: Basics. AAOS Annual Meeting, Chicago, Ill. March 2013.

Beaty, J. The Orthopaedic Lecture: Effective Delivery. AAOS Annual Meeting, Chicago, Ill. March 2013.

Beaty, J. Developing Leadership Through Orthopaedic Organizations. AAOS Annual Meeting, Chicago, Ill. March 2013.

Beaty, J. The Kids You See on Call: Slipped Capital Femoral Epiphysis. AAOS Annual Meeting, Chicago, Ill. March 2013.

Beaty, J. Child Abuse: Nonaccidental Injury. AAOS Annual Meeting, Chicago, Ill. March 2013.

Beaty, J. Management of the Multiply Injured Child. AAOS Annual Meeting, Chicago, Ill. March 2013.

Beaty, J.H., Warner, W.C., Sawyer, J.R., Kelly, D.M., Larsen, Moisan, Witte, Elzey. *Medial Ulnar Collateral Ligament Origin on the Medial Epicondylar Apophysis in the Skeletally Immature Elbow*: An MRI Anatomical Study. Presented at the American Academy of Orthopaedic Surgeons, Chicago, Ill., March 2013.

Beaty, J.H., Warner, W.C., Sawyer, J.R., Kelly, D.M., Larsen, Moisan, Witte, Elzey. *Medial Ulnar Collateral Ligament Origin on the Medial Epicondylar Apophysis in the Skeletally Immature Elbow*: An MRI Anatomical Study. Poster presented at POSNA annual meeting, Toronto, Ontario, May 2013.

Beaty, J.H., Warner, W.C., Sawyer, J.R., Spence, D., Kelly, D.M., Pretell, Murphy, Moisan. *Surgical Treatment of Symptomatic Accessory Navicular in Children and Adolescent: Is Simple Excision Enough?* ePoster presented at POSNA annual meeting, Toronto, Ontario, May 2013.

William C. Warner Jr., MD

William C Warner, MD, Beaty, JH, Jeffrey I Kutsikovich, MD, Christopher M Hopkins, MD, Edwin W Gannon III, Jeffrey R Sawyer, MD, David D Spence, MD, Derek M Kelly, MD. Factors that Predict Instability in Pediatric Diaphyseal Both Bone Forearm Fractures. ASSH ePoster. Sep 10-12. Seattle, WA.

Cervical Spine Trauma Immobilization Protocols in Young Children. How Often Are These Protocols Followed? Factors that Predict Instability in Pediatric Diaphyseal Both Bone Forearm Fractures. Weldy, Beaty, Spence, Kelly, Sawyer, Warner, Jr. OTA poster. San Diego, CA. Oct. 7-10, 2015.

Factors that Predict Instability in Pediatric Diaphyseal Both Bone Forearm Fractures. Kutsikovich, Hopkins, Gannon III, Beaty, Warner, Sawyer, Spence, Kelly. ASSH eposter. Seattle, WA. Sept. 10-12, 2015; OTA podium. San Diego, CA. Oct. 7-10, 2015.

Changing Trends in Pediatric Spine Surgery in The United States: 1997-2012. Kelly, Warner, Sawyer, Copley. SRS Podium. Minneapolis, MN. Sept. 30-Oct. 3, 2015.

Warner, Beaty J, Bert, Biggers, Moisan, Sawyer, Kelly. Fracture of the Medial Humeral Epicondyle in Children: A Comparison of Operative and Nonoperative Management (accepted Podium). American Academy of Orthopaedic Surgeons, New Orleans, March 2014.

Warner, Beaty, Thompson, Kelly, Rush, Spence, Moisan, Sawyer. Intra and Inter-Observer Reliability and the Role of Fracture Morphology in Classifying Femoral Shaft Fractures in Children (poster). European Pediatric Orthopaedic Society, Belgium, April 2014.

Warner William C. Jr, MD, Robert F. Murphy, MD, Austin R. Davidson, BS, Derek M. Kelly, MD, David D. Spence, MD, and Jeffrey R. Sawyer MD. Sub-axial Cervical Spine Injuries in Children and Adolescents (e poster). European Pediatric Orthopaedic Society, Belgium, April 2014.

Warner William C. Jr. MD, Beaty James H. MD, Ryan Murphy BS, Derek M. Kelly MD, Alice Moisan RN, Norfleet Thompson MD, David D. Spence MD, Jeffrey R. Sawyer MD. Transverse Femoral Shaft Fractures are a Better Predictor of Non-Accidental Trauma than Spiral Fractures in Young Children(poster). European Pediatric Orthopaedic Society, Belgium, April 2014.

Warner William C. MD, Beaty James H. MD, Byron F. Stephens MD, Jeffrey R. Sawyer MD, David D. Spence MD, Alice A. Moisan BSN and Derek M. Kelly MD Interleukin-6 in Pediatric Musculoskeletal Infection: A Pilot Study (Podium). European Pediatric Orthopaedic Society, Belgium, April 2014.

Warner William C Jr, MD, Beaty James H, MD, Juan Pretell-Mazzini, MD, Vinayak Perake, MD; Derek M. Kelly, MD, Jeffrey R Sawyer, MD, Alice A Moisan, BSN, David D Spence, MD. Outcomes And Complications Of Tibial Tubercle Fractures Within The Pediatric Population. A Systematic Review Of The Literature (e-poster). European Pediatric Orthopaedic Society, Belgium, April 2014.

Warner William C. Jr. MD, Beaty James H. MD, Ryan Murphy BS, Derek M. Kelly MD, Alice Moisan RN, Norfleet Thompson MD, David D. Spence MD, Jeffrey R. Sawyer MD. Transverse Femoral Shaft Fractures are a Better Predictor of Non-Accidental Trauma than Spiral Fractures in Young Children accepted podium. POSNA, Hollywood, Ca., April-May 2014.

Warner William C. Jr, MD, Robert F. Murphy, MD, Austin R. Davidson, BS, Derek M. Kelly, MD, David D. Spence, MD, and Jeffrey R. Sawyer MD Sub-axial cervical spine injuries in children and adolescents accepted e poster. POSNA, Hollywood, Ca., April-May 2014.

Warner William C. MD, Beaty James H. MD, Byron F. Stephens MD, Jeffrey R. Sawyer MD, David D. Spence MD, Alice A. Moisan BSN and Derek M. Kelly MD. Interleukin-6 in Pediatric Musculoskeletal Infection: A Pilot Study accepted e poster. POSNA, Hollywood, Ca., April-May 2014.

Jeffrey R. Sawyer, MD

Sawyer, Jeffrey R, MD, William C Warner, MD, Beaty, JH, Jeffrey I Kutsikovich, MD, Christopher M Hopkins, MD, Edwin W Gannon III, David D Spence, MD, Derek M Kelly, MD. Factors that Predict Instability in Pediatric Diaphyseal Both Bone Forearm Fractures. ASSH ePoster. Sep 10-12. Seattle, WA.

Sawyer, Jeffrey R, MD, John D Roaten MD, Joseph Yellin BA, John M. Flynn MD, Sumeet Garg MD, Micaela Cyr BA, Lindsay M. Andras MD, Alexander M. Broom BA. Pediatric Femur Fracture Management: A Multicenter Analysis of the Trends Pre and Post 2009 AAOS Clinical Practice Guidelines . AAOS March 1-5, 2016. Orlando, FL.

Sawyer, Jeffrey R, Ryan Murphy, CSSG, GSSG. Complications and Radiographic Outcomes of Posterior Spinal Fusion (PSF) and Observation (OB) in Patients Who Have Undergone Distraction-Based Treatment for Early Onset Scoliosis (EOS). POSNA April 27-30, 2016/April 6-9, 2016 Indianapolis, IN/Rome, IT.

Sawyer, Jeffrey R, Ryan Murphy, Matt Stewart, Moisan. Characterization of Radiation Exposure in Adult and Pediatric Populations with Osteogenesis Imperfecta. EPOS April 6-9, 2016. Rome, IT.

Sawyer, Jeffrey R, John D Roaten, Joseph Yellin BA, John M. Flynn MD, Sumeet Garg MD, Micaela Cyr BA, Lindsay M. Andras MD, Alexander M. Broom BA. Pediatric Femur Fracture Management: A Multicenter Analysis of the Trends Pre and Post 2009 AAOS Clinical Practice Guidelines. POSNA/EPOS April 27-30, 2016/April 6-9, 2016. Indianapolis, IN/Rome, IT.

Sawyer, Jeffrey R, Hopkins, Kutsikovich, DDS, DMK. Do All Pediatric Both Bone Forearm Fractures Require Immediate Reduction in the Emergency Room (ER)? EPOS April 6-9, 2016 Rome, IT.

Sawyer, Jeffrey R, Amoli, Edmonds. Do Males and Females Get Different Jobs Within Pediatric Orthopedics? A Comparison from the POSNA Needs Assesment Survey. POSNA/EPOS April 27-30, 2016/April 6-9, 2016 Indianapolis, IN/Rome, IT.

Sawyer, Jeffrey R, Chris Loftis, Trey Eubanks, DMK. Child Safety Restraint Status and Age in Motor Vehicle Collisions Predict Type and Severity of Traumatic Injuries POSNA/EPOS April 27-30, 2016/April 6-9, 2016 Indianapolis, IN/Rome, IT.

Complications and Radiographic Outcomes of Posterior Spinal Fusion (PSF) in Patients with Spinal Muscular Atrophy (SMA) Following Growth Friendly Treatment. Sawyer, Mendoça, Murphy, Flournory, et al. ICEOS eposter. Boston, MA. Nov. 19-20, 2015.

Cervical Spine Trauma Immobilization Protocols in Young Children. How Often Are These Protocols Followed? Factors that Predict Instability in Pediatric Diaphyseal Both Bone Forearm Fractures. Weldy, Beaty, Spence, Kelly, Sawyer, Warner, Jr. OTA poster. San Diego, CA. Oct. 7-10, 2015.

Factors that Predict Instability in Pediatric Diaphyseal Both Bone Forearm Fractures. Kutsikovich, Hopkins, Gannon III, Beaty, Warner, Sawyer, Spence, Kelly. ASSH eposter. Seattle, WA. Sept. 10-12, 2015; OTA podium. San Diego, CA. Oct. 7-10, 2015.

A Supply and Demand Analysis of the Orthopaedic Trauma Surgeon Workforce in the United States. Sielatycki, Sawyer, Mir. OTA. San Diego, CA. Oct. 7-10, 2015.

Changing Trends in Pediatric Spine Surgery in The United States: 1997-2012. Kelly, Warner, Sawyer, Copley. SRS Podium. Minneapolis, MN. Sept. 30-Oct. 3, 2015.

The Evolving State of Acute Pediatric Septic Arthritis and Osteomyelitis. Franklin, Kelly, Sawyer. POSA eposter #46. Atlanta, GA. April 29-May 2, 2015.

Early Career Experience of Pediatric Orthopaedic Fellows: What to Expect and Need for Their Services. Glotzbecker, Shore, Fletcher, Larson, Hydorn, Sawyer. POSNA Podium. Atlanta, GA. April 29, 2015.

The Evolving State of Acute Pediatric Septic Arthiritis and Osteomyelitis. Franklin, Sawyer, Kelly. EPOS Poster. Marseille, France. April 15-18, 2015.

A 10-Year Multi-Center Review of Current Trends in the Treatment of Pediatric Femoral Shaft Fracture. Roaten, Sawyer, CHOP, UCLA. EPOS eposter #644, Marseille, France. April 15-18, 2015.

Sawyer, Warner, Beaty J, Bert, Biggers, Moisan, Kelly. Fracture of the Medial Humeral Epicondyle in Children: A Comparison of Operative and Nonoperative Management (accepted Podium). American Academy of Orthopaedic Surgeons, New Orleans, March 2014.

Sawyer, Beaty, Thompson, Kelly, Rush, Warner, Spence, Moisan. Intra and Inter-Observer Reliability and the Role of Fracture Morphology in Classifying Femoral Shaft Fractures in Children (poster). European Pediatric Orthopaedic Society, Belgium, April 2014.

Sawyer Jeffrey R. MD Warner William C. Jr, MD, Robert F. Murphy, MD, Austin R. Davidson, BS, Derek M. Kelly, MD, David D. Spence, MD. Sub-axial Cervical Spine Injuries in Children and Adolescents (e poster). European Pediatric Orthopaedic Society, Belgium, April 2014.

Sawyer Jeffrey R. MD, Beaty James H. MD, Ryan Murphy BS, Derek M. Kelly MD, William C. Warner Jr. MD, Alice Moisan RN, Norfleet Thompson MD, David D. Spence MD.Transverse Femoral Shaft Fractures are a Better Predictor of Non-Accidental Trauma than Spiral Fractures in Young Children(poster). European Pediatric Orthopaedic Society, Belgium, April 2014.

Sawyer Jeffrey R. MD, Beaty James H. MD, Byron F. Stephens MD, William C. Warner MD, David D. Spence MD, Alice A. Moisan BSN and Derek M. Kelly MD Interleukin-6 in Pediatric Musculoskeletal Infection: A Pilot Study (Podium). European Pediatric Orthopaedic Society, Belgium, April 2014.

Sawyer Jeffrey R. MD, Beaty James H. MD, Sameer M. Naranje MD, Derek M. Kelly MD, Tamekia L. Jones PhD. Changes in the Treatment of Pediatric Femur Fractures: Trends from United States Kids' Inpatient Database (KID) (Podium). European Pediatric Orthopaedic Society, Belgium, April 2014.

Sawyer Jeffrey R, MD, Beaty James H, MD, Juan Pretell-Mazzini, MD, Vinayak Perake, MD; Derek M. Kelly, MD, Alice A Moisan, BSN, David D Spence, MD, William C Warner, Jr, MD. Outcomes And Complications Of Tibial Tubercle Fractures Within The Pediatric Population. A Systematic Review Of The Literature (e-poster). European Pediatric Orthopaedic Society, Belgium, April 2014.

Sawyer Jeffrey R. MD; Kody K. Barrett, BA; David L. Skaggs, MD; Lindsay Andras, MD; Alice Moisan, BSN, RN, CCRP; Christine Goodbody, BS; Jack Flynn, MD Supracondylar Fractures with Isolated Anterior Interosseous Nerve Injuries: Are they Urgent Cases? (Podium). European Pediatric Orthopaedic Society, Belgium, April 2014.

Sawyer Jeffrey R. MD Beaty James H. MD, Ryan Murphy BS, Derek M. Kelly MD, William C. Warner Jr. MD, Alice Moisan RN, Norfleet Thompson MD, David D. Spence MD. Transverse Femoral Shaft Fractures are a Better Predictor of Non-Accidental Trauma than Spiral Fractures in Young Children accepted podium. POSNA, Hollywood, Ca., April-May 2014.

Sawyer Jeffrey R. MD, Warner William C. Jr, MD, Robert F. Murphy, MD, Austin R. Davidson, BS, Derek M. Kelly, MD, David D. Spence, MD. Sub-axial cervical spine injuries in children and adolescents accepted e poster. POSNA, Hollywood, Ca., April-May 2014.

Sawyer Jeffrey R. MD, Beaty James H. MD, Byron F. Stephens MD, William C. Warner MD, David D. Spence MD, Alice A. Moisan BSN and Derek M. Kelly MD. Interleukin-6 in Pediatric Musculoskeletal Infection: A Pilot Study accepted e poster. POSNA, Hollywood, Ca., April-May 2014.

Sawyer, Jeffrey MD; Sumeet Garg, MD; Micaela Cyr, BA; Michael Glotzbecker, MD; Patrick Carry, BA; John Smith, MD; Joshua Pahys, MD; Scott Luhmann, MD; Jack Flynn, MD; Ron El-Hawary, MD; Michael Vitale, MD; Tricia St. Hilaire, MPH A Multicenter Retrospective Cohort Analysis of Infection Characteristics and Rates with VEPTR Surgery: 2007 to Present accepted eposter. POSNA, Hollywood, Ca., April-May 2014.

Derek Kelly, MD

Kelly, Derek M, William C Warner, MD, Beaty, JH, Jeffrey I Kutsikovich, MD, Christopher M Hopkins, MD, Edwin W Gannon III, Jeffrey R Sawyer, MD, David D Spence, MD. Factors that Predict Instability in Pediatric Diaphyseal Both Bone Forearm Fractures. ASSH ePoster. Sep 10-12. Seattle, WA.

Kelly, Derek M, David Heinsch, MD; Alice Moisan, BSN, RN; Leslie Rhodes, DNP. Risk Factors for Surgical Release in Clubfoot Treated by the Ponseti Method: Utility of Radiographic. EPOS April 6-9, 2016. Rome, IT.

Kelly, Derek M, Sawyer, Jeffrey R, Hopkins, Kutsikovich, DDS. Do All Pediatric Both Bone Forearm Fractures Require Immediate Reduction in the Emergency Room (ER)? EPOS April 6-9, 2016 Rome, IT.

Kelly, Derek M, Jeff Kutsikovich, Wyn Gannon. Factors that Predict Instability in Both Bone Forearm Fractures .POSNA/EPOS April 27th 4:11-4:15pm/April 6-9, 2016. Indianapolis, IN/Rome, IT.

Kelly, Derek M, Sawyer, Jeffrey R, Chris Loftis, Trey Eubanks. Child Safety Restraint Status and Age in Motor Vehicle Collisions Predict Type and Severity of Traumatic Injuries POSNA/EPOS April 27-30, 2016/April 6-9, 2016 Indianapolis, IN/Rome, IT.

Cervical Spine Trauma Immobilization Protocols in Young Children. How Often Are These Protocols Followed? Factors that Predict Instability in Pediatric Diaphyseal Both Bone Forearm Fractures. Weldy, Beaty, Spence, Kelly, Sawyer, Warner, Jr. OTA poster. San Diego, CA. Oct. 7-10, 2015.

Kutsikovich, Hopkins, Gannon III, Beaty, Warner, Sawyer, Spence, Kelly. ASSH eposter. Seattle, WA. Sept. 10-12, 2015; OTA podium. San Diego, CA. Oct. 7-10, 2015.

Changing Trends in Pediatric Spine Surgery in The United States: 1997-2012. Kelly, Warner, Sawyer, Copley. SRS Podium. Minneapolis, MN. Sept. 30-Oct. 3, 2015.

The Evolving State of Acute Pediatric Septic Arthritis and Osteomyelitis. Franklin, Kelly, Sawyer. POSNA eposter #46. Atlanta, GA. April 29-May2, 2015. EPOS Poster. Marseille, France. April 15-18, 2015.

Kelly, Sawyer, Warner, Beaty J, Bert, Biggers, Moisan. Fracture of the Medial Humeral Epicondyle in Children: A Comparison of Operative and Nonoperative Management (accepted Podium). American Academy of Orthopaedic Surgeons, New Orleans, March 2014.

Kelly, Beaty, Thompson, Rush, Warner, Spence, Moisan, Sawyer. Intra and Inter-Observer Reliability and the Role of Fracture Morphology in Classifying Femoral Shaft Fractures in Children (poster). European Pediatric Orthopaedic Society, Belgium, April 2014.

Kelly, Derek M., MD, Sawyer Jeffrey R. MD Warner William C. Jr, MD, Robert F. Murphy, MD, Austin R. Davidson, BS, David D. Spence, MD. Sub-axial Cervical Spine Injuries in Children and Adolescents (e poster). European Pediatric Orthopaedic Society, Belgium, April 2014.

Kelly Derek M. MD, Beaty James H. MD, Ryan Murphy BS, William C. Warner Jr. MD, Alice Moisan RN, Norfleet Thompson MD, David D. Spence MD, Jeffrey R. Sawyer MD. Transverse Femoral Shaft Fractures are a Better Predictor of Non-Accidental Trauma than Spiral Fractures in Young Children (poster). European Pediatric Orthopaedic Society, Belgium, April 2014.

Kelly Derek M. MD, Beaty James H. MD, Byron F. Stephens MD, Jeffrey R. Sawyer MD, William C. Warner MD, David D. Spence MD, Alice A. Moisan BSN. Interleukin-6 in Pediatric Musculoskeletal Infection: A Pilot Study (Podium). European Pediatric Orthopaedic Society, Belgium, April 2014.

Kelly Derek M. MD, Beaty James H. MD, Sameer M. Naranje MD, Jeffrey R. Sawyer MD, Tamekia L. Jones PhD. Changes in the Treatment of Pediatric Femur Fractures: Trends from United States Kids' Inpatient Database (KID) (Podium). European Pediatric Orthopaedic Society, Belgium, April 2014.

Kelly Derek M., MD, Beaty James H, MD, Juan Pretell-Mazzini, MD, Vinayak Perake, MD; Jeffrey R Sawyer, MD, Alice A Moisan, BSN, David D Spence, MD, William C Warner, Jr, MD. Outcomes And Complications Of Tibial Tubercle Fractures Within The Pediatric Population. A Systematic Review Of The Literature (e-poster). European Pediatric Orthopaedic Society, Belgium, April 2014.

Kelly Derek M. MD, Beaty James H. MD, Ryan Murphy BS, William C. Warner Jr. MD, Alice Moisan RN, Norfleet Thompson MD, David D. Spence MD, Jeffrey R. Sawyer MD. Transverse Femoral Shaft Fractures are a Better Predictor of Non-Accidental Trauma than Spiral Fractures in Young Children accepted podium. POSNA, Hollywood, Ca., April-May 2014.

Kelly Derek M., MD, Warner William C. Jr, MD, Robert F. Murphy, MD, Austin R. Davidson, BS, David D. Spence, MD, and Jeffrey R. Sawyer MD. Sub-axial cervical spine injuries in children and adolescents accepted e poster. POSNA, Hollywood, Ca., April-May 2014.

Kelly Derek M. MD. Beaty James H. MD, Byron F. Stephens MD, Jeffrey R. Sawyer MD, William C. Warner MD, David D. Spence MD, Alice A. Moisan BSN. Interleukin-6 in Pediatric Musculoskeletal Infection: A Pilot Study accepted e poster. POSNA, Hollywood, Ca., April-May 2014.

David Spence, MD

David D Spence, MD, William C Warner, MD, Beaty, JH, Jeffrey I Kutsikovich, MD, Christopher M Hopkins, MD, Edwin W Gannon III, Jeffrey R Sawyer, MD, Derek M Kelly, MD. Factors that Predict Instability in Pediatric Diaphyseal Both Bone Forearm Fractures. ASSH ePoster. Sep 10-12. Seattle, WA.

Cervical Spine Trauma Immobilization Protocols in Young Children. How Often Are These Protocols Followed? Factors that Predict Instability in Pediatric Diaphyseal Both Bone Forearm Fractures. Weldy, Beaty, Spence, Kelly, Sawyer, Warner, Jr. OTA poster. San Diego, CA. Oct. 7-10, 2015.

Factors that Predict Instability in Pediatric Diaphyseal Both Bone Forearm Fractures. Kutsikovich, Hopkins, Gannon III, Beaty, Warner, Sawyer, Spence, Kelly. ASSH eposter. Seattle, WA. Sept. 10-12, 2015; OTA podium. San Diego, CA. Oct. 7-10, 2015.

Spence, Beaty, Thompson, Kelly, Rush, Warner, Moisan, Sawyer. Intra and Inter-Observer Reliability and the Role of Fracture Morphology in Classifying Femoral Shaft Fractures in Children (poster). European Pediatric Orthopaedic Society, Belgium, April 2014.

Spence David D., MD, Sawyer Jeffrey R. MD Warner William C. Jr, MD, Robert F. Murphy, MD, Austin R. Davidson, BS, Derek M. Kelly, MD. Sub-axial Cervical Spine Injuries in Children and Adolescents (e poster). European Pediatric Orthopaedic Society, Belgium, April 2014.

Spence David D. MD, Beaty James H. MD, Ryan Murphy BS, Derek M. Kelly MD, William C. Warner Jr. MD, Alice Moisan RN, Norfleet Thompson MD, Jeffrey R. Sawyer MD. Transverse Femoral Shaft Fractures are a Better Predictor of Non-Accidental Trauma than Spiral Fractures in Young Children (poster). European Pediatric Orthopaedic Society, Belgium, April 2014.

Spence David D. MD, Beaty James H. MD, Byron F. Stephens MD, Jeffrey R. Sawyer MD, William C. Warner MD, Alice A. Moisan BSN and Derek M. Kelly MD. Interleukin-6 in Pediatric Musculoskeletal Infection: A Pilot Study (Podium). European Pediatric Orthopaedic Society, Belgium, April 2014.

Spence David D, MD, Beaty James H, MD, Juan Pretell-Mazzini, MD, Vinayak Perake, MD; Derek M. Kelly, MD, Jeffrey R Sawyer, MD, Alice A Moisan, BSN, William C Warner, Jr, MD. Outcomes And Complications Of Tibial Tubercle Fractures Within The Pediatric Population. A Systematic Review Of The Literature (e-poster). European Pediatric Orthopaedic Society, Belgium, April 2014.

Spence David D. MD, Beaty James H. MD, Ryan Murphy BS, Derek M. Kelly MD, William C. Warner Jr. MD, Alice Moisan RN, Norfleet Thompson MD, Jeffrey R. Sawyer MD. Transverse Femoral Shaft Fractures are a Better Predictor of Non-Accidental Trauma than Spiral Fractures in Young Children accepted podium. POSNA, Hollywood, Ca., April-May 2014.

Spence David D., MD, Warner William C. Jr, MD, Robert F. Murphy, MD, Austin R. Davidson, BS, Derek M. Kelly, MD, and Jeffrey R. Sawyer MD. Sub-axial cervical spine injuries in children and adolescents accepted e poster. POSNA, Hollywood, Ca., April-May 2014.

Spence David D. MD, Beaty James H. MD, Byron F. Stephens MD, Jeffrey R. Sawyer MD, William C. Warner MD, Alice A. Moisan BSN and Derek M. Kelly MD. Interleukin-6 in Pediatric Musculoskeletal Infection: A Pilot Study accepted e poster. POSNA, Hollywood, Ca., April-May 2014.

Spence, D. Hip preservation in the young adolescent. Pediatric Orthopaedics: Common Conditions and the Pediatric Hip. Le Bonheur, Memphis, Tenn. Nov. 2, 2013.

Spence, D. Knee pain: Common and uncommon causes. Pediatric Orthopaedics: Common Conditions and the Pediatric Hip. Le Bonheur, Memphis, Tenn. Nov. 2, 2013

Spence, D. Torticollis: Diagnosis, treatment and evidence-based practice. TPTA, Memphis, Tenn. Sept. 27, 2013.

Spence, D., Kelly, D.M., Sawyer, J.R., Warner, W.C., Beaty, J.H., Pretell, Murphy, Moisan. *Surgical Treatment of Symptomatic Accessory Navicular in Children and Adolescent: Is Simple Excision Enough?* ePoster presented at POSNA annual meeting, Toronto, Ontario, May 2013.

David D. Spence, MD; Jon Paul DiMauro, MD; Patricia Miller, MS; Michael P. Glotzbecker, MD; Daniel Hedequist, MD; Benjamin J. Shore, MD. *Avascular Necrosis after Femoral Neck Fracture: Analysis of Risk Factors.* Presented at POSNA annual meeting, Toronto, Ontario, May 2013.

David D. Spence, MD; Jon Paul DiMauro, MD; Michael P. Glotzbecker, MD; Samantha A. Spencer, MD; Daniel Hedequist, MD; Benjamin J. Shore, MD, FRCSC. *External Fixation for Pediatric Diaphyseal Tibia Fractures: A Comparison between Taylor Spatial Frame and Uniplanar External Fixation.* ePoster presented at POSNA annual meeting, Toronto, Ontario, May 2013.